UNIVERSITÀ - OSPEDALE di PADOVA

MEDICINA NUCLEARE

LA MEDICINA NUCLEARE NELLE PATOLOGIE NEUROLOGICHE

Franco Bui, Diego Cecchin

TECNOLOGIE

SPET

SINGLE PHOTON EMISSION TOMOGRAPHY

PET

POSITRON EMISSION TOMOGRAPHY

Az. Ospedale - Università di Padova - Medicina Nucleare - www.unipd.it/nucmed/

BRAIN SPET - *SPECT*

SPET - Radiofarmaci

- Radiofarmaci che studiano la **perfusione**
- Radiofarmaci che studiano la **cellularità**
- Radiofarmaci **recettoriali**
- Radiogas che quantificano il **flusso**

SPET PERFUSORIA: Radiofarmaci

Composti lipofilici che superano la barriera emato-encefalica subendo una conversione intracellulare a composti idrofilici che restano intrappolati nelle cellule cerebrali

SPET PERFUSORIA: Metodologia

- Posizionamento di un ' agocannula in vena antecubitale, tenuta pervia con fisiologica
- Paziente supino, in ambiente tranquillo, con luce offuscata, senza interazioni con l'equipe, per almeno 15' prima della somministrazione del radiofarmaco
- Somministrazione del radiofarmaco
- Acquisizione delle immagini dopo 30-60'

SPET di Perfusione: Premesse…

ECD = Ethyl Cysteinate Dimer

HMPAO = HexaMethyl Propylene Amine Oxime

NON forniscono una quantificazione assoluta del flusso ma una stima delle differenze di flusso (destro/sinistro, zone di riferimento ecc). Quindi:

Perfusione relativa !

SPET CEREBRALE PERFUSORIA

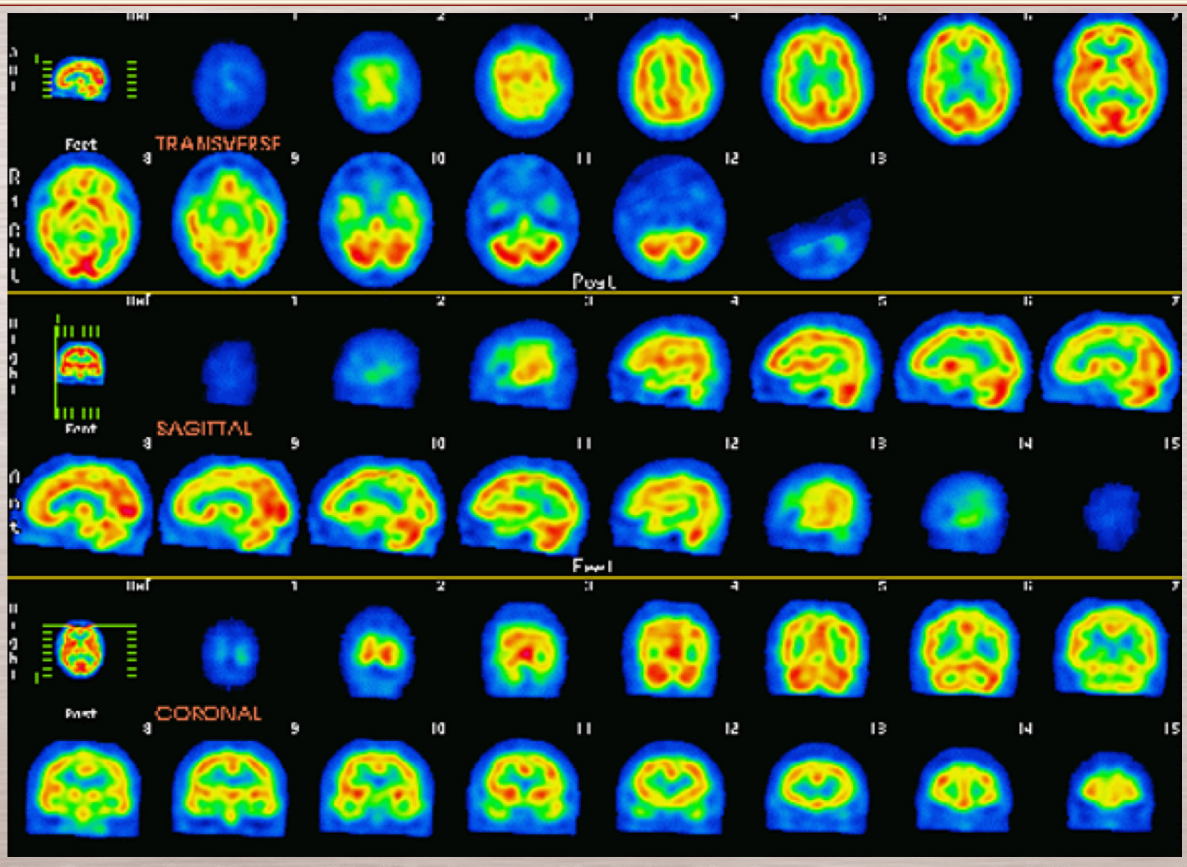

SPET CEREBRALE PERFUSORIA

DECLINO COGNITIVO

ALZHEIMER (TIPICO BILAT)

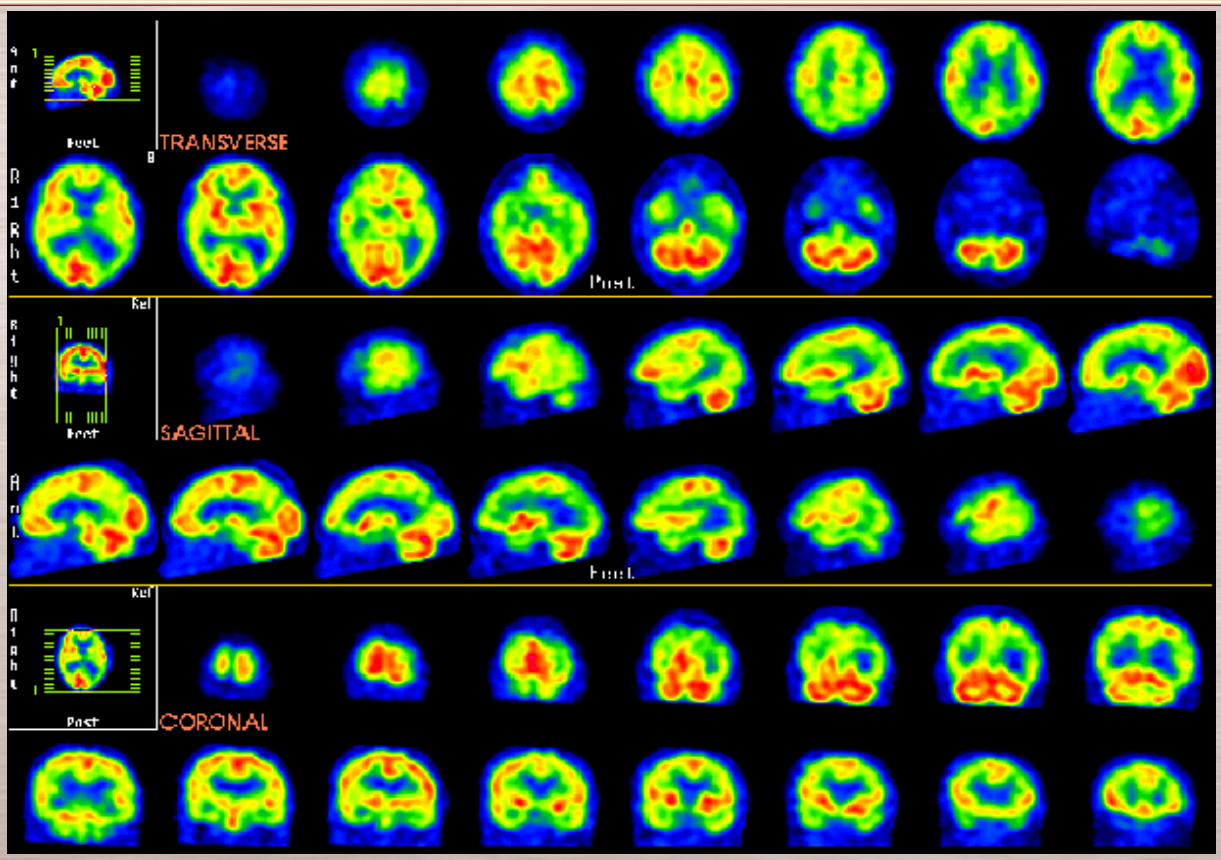

DEMENZA FRONTALE

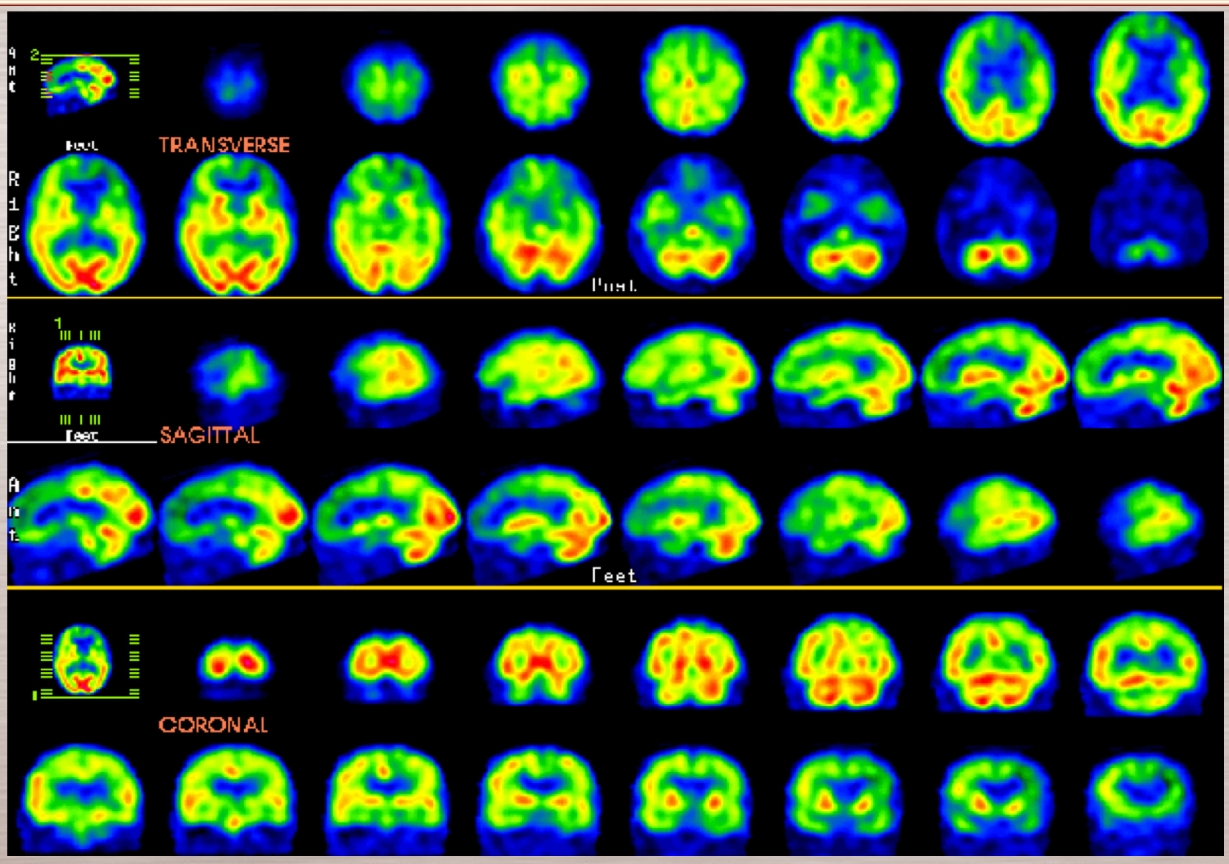

SPET CEREBRALE PERFUSORIA

PATOLOGIA VASCOLARE

ICTUS

SPET di Perfusione: Razionale

Di norma la SPET è utile in associazione imaging morfologico (MRI, CT), ma possiede anche valore a se stante perché le alterazioni funzionali precedono le alterazioni anatomiche

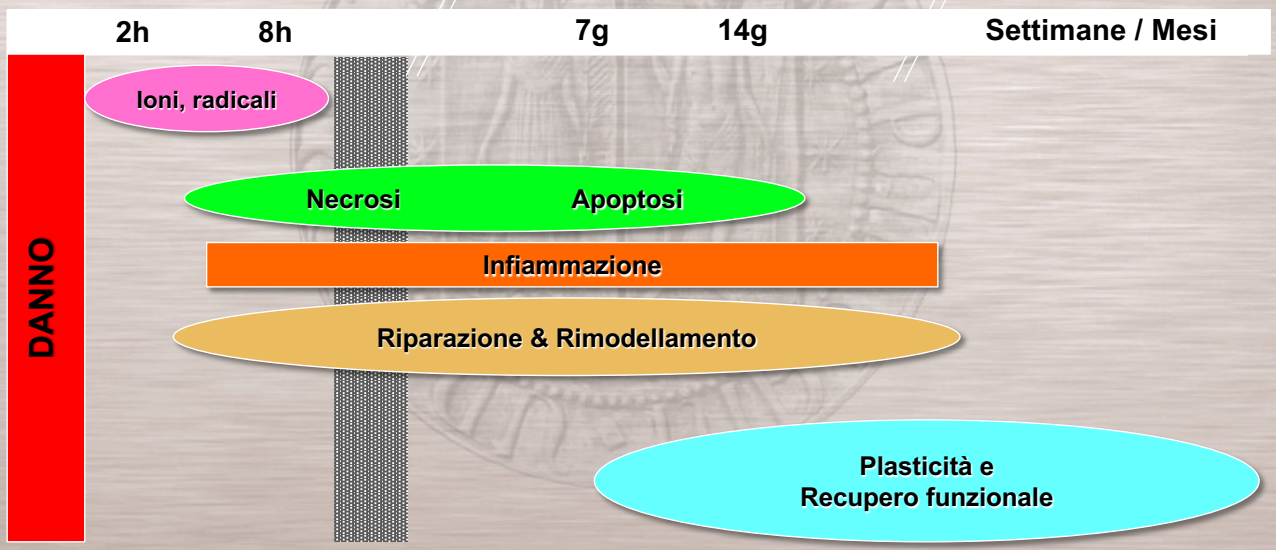

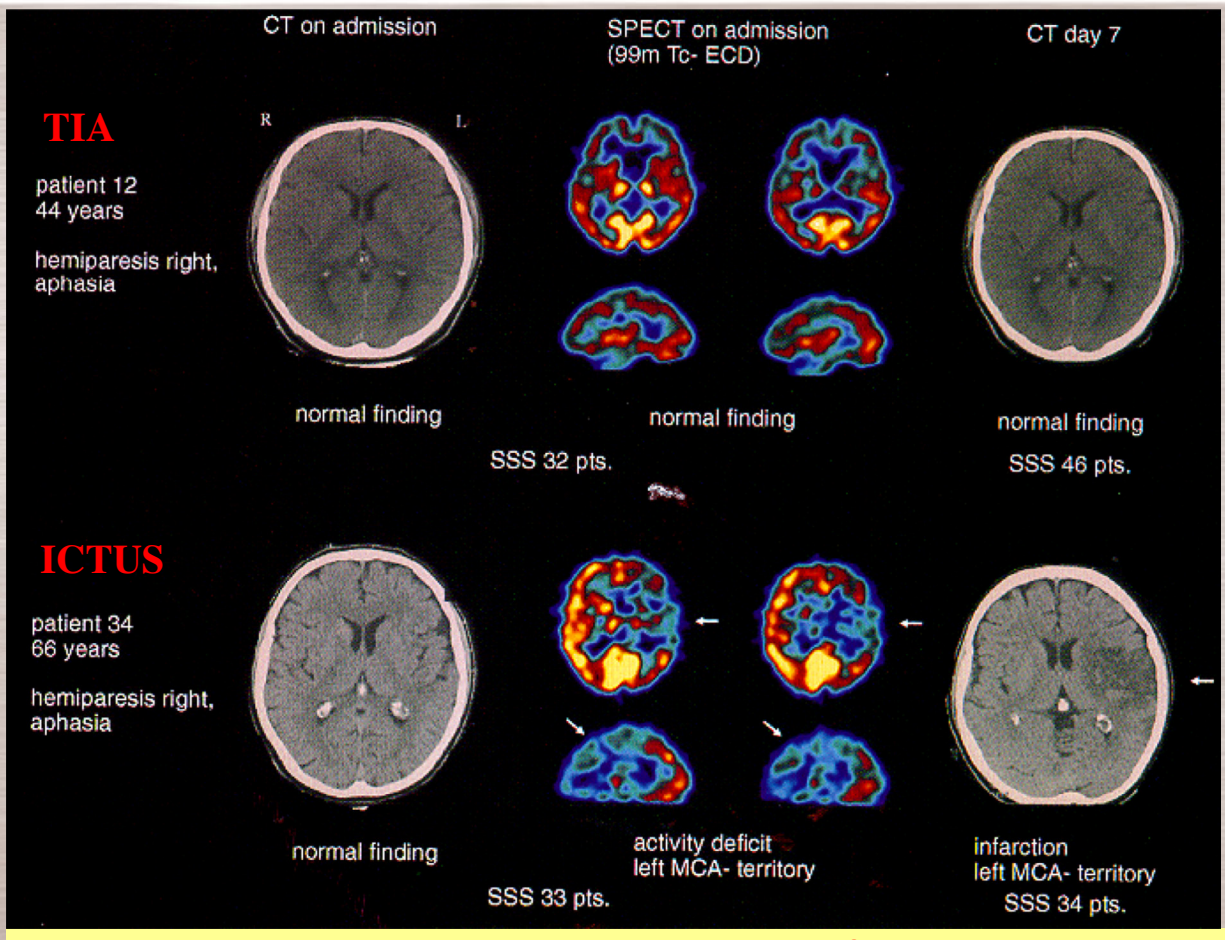

Differentiation Between Transient Ischemic Attack and Ischemic Stroke within the first SIX hours after onset of Symptoms

Az. Ospedale - Università di Padova - Medicina Nucleare - www.unipd.it/nucmed/

INFARTO A. Cerebrale MEDIA DX

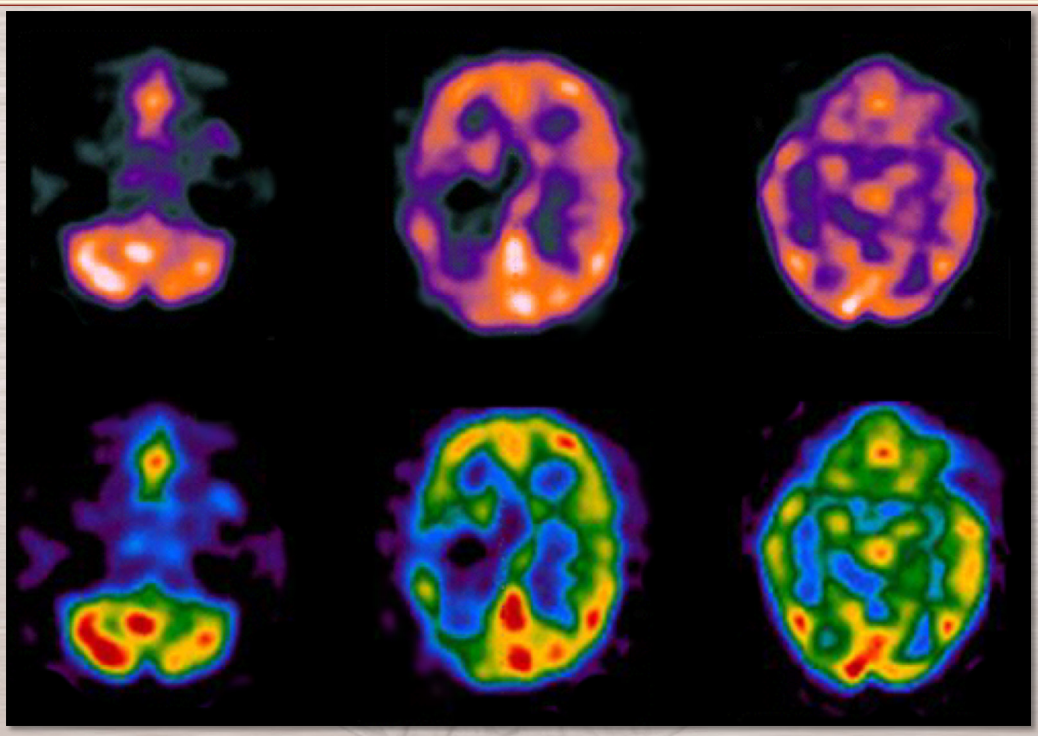

Netta ipoperfusione fronto-temporo-parietale dx e lieve ipoperfusione del cervelletto sn

Infarto ACM sn

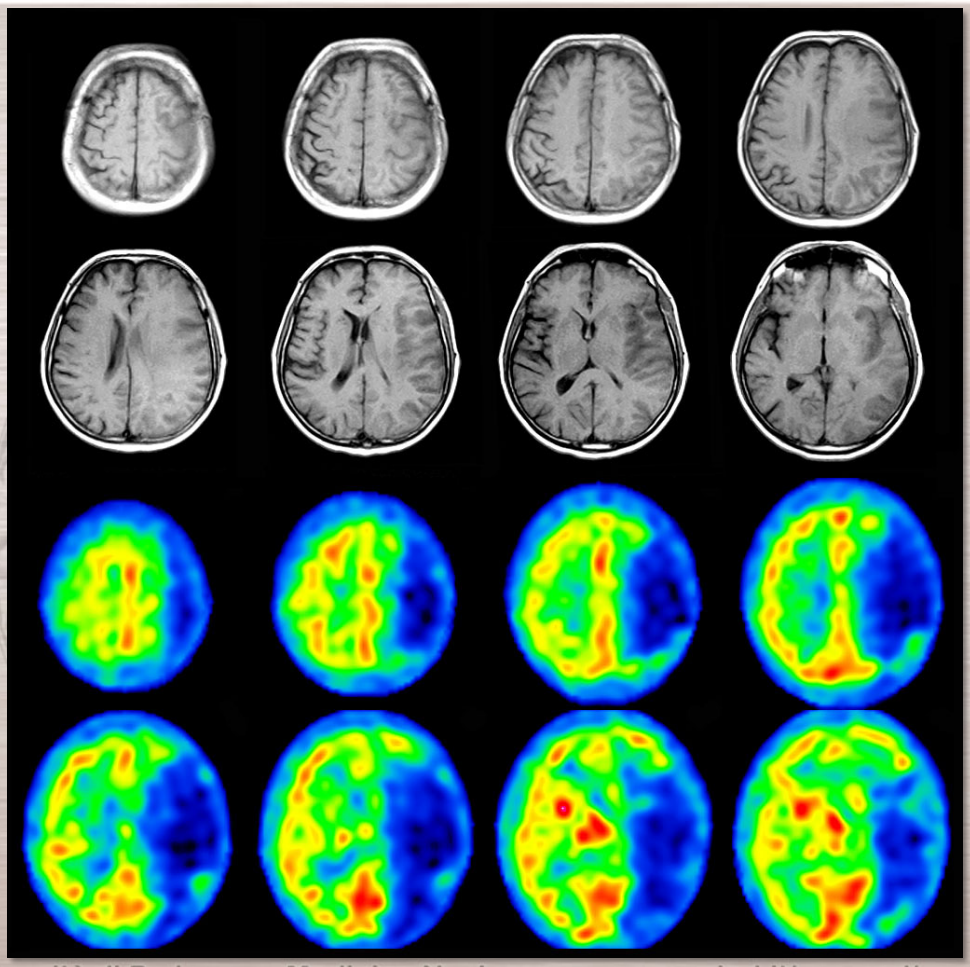

INFARTO FRONTO-TEMPORALE DX

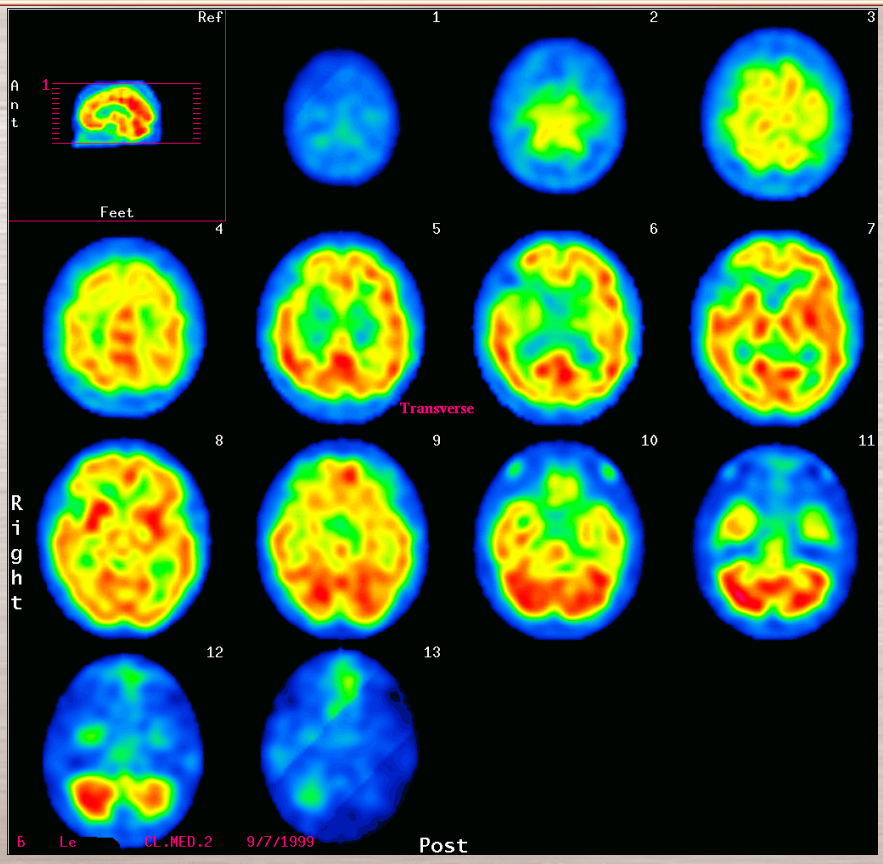

INFARTO FRONTO-TEMPORALE DX

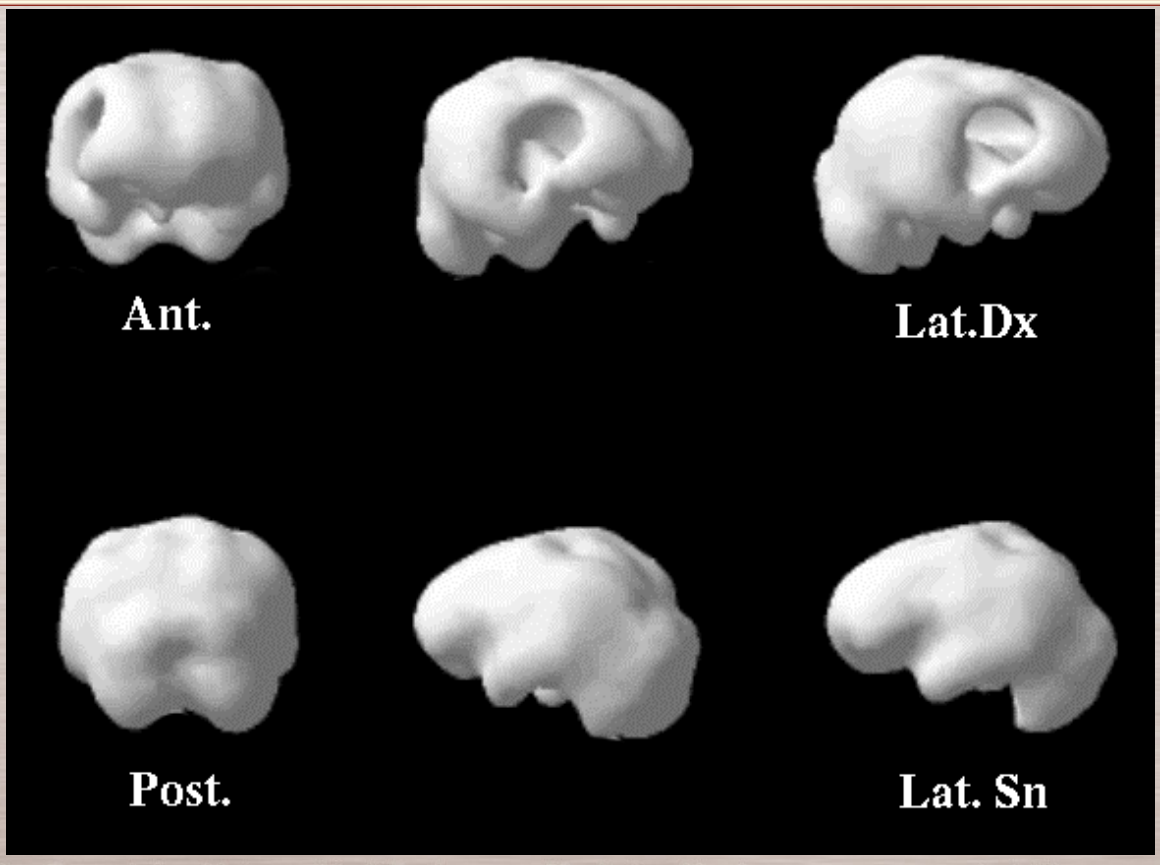

SPET CEREBRALE PERFUSORIA

EPILESSIA

EPILESSIA

- Sintomi complessi, caratterizzati da *eccessivo eccitamento neuronale*
- In particolare e. focale, spesso farmaco-resistente
- Ricerca di focolaio epilettogeno (che può o meno coincidere con una lesione anatomica all'imaging morfologico)

	Studio ICTALE	ed Inter-ICTALE
Sensibilità:	80-95%	55-80%

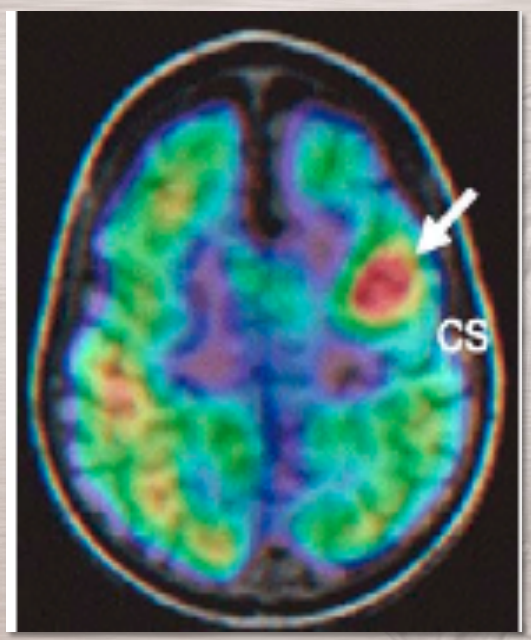

Spect di perfusione in fase ICTALE in b. di 2.5 anni

Co-registrazione con MRI:

Focolaio nel solco centrale SN, davanti al giro pre-centrale.

Monitoraggio EEG: concordante

SPET CEREBRALE PERFUSORIA

MORTE CEREBRALE

MORTE CEREBRALE

Legge n. 578, 29/12/93:

… la morte cerebrale è considerata la cessazione irreversibile di tutte le funzioni dell'encefalo …

DM n. 582, 22/8/94:

… accertare l'assenza di flusso ematico cerebrale nei casi in cui i mezzi ordinari non siano attendibili …

MORTE CEREBRALE

Condizioni che richiedono di determinare l'assenza di flusso cerebrale per la diagnosi di morte:

- **Presenza di fattori concomitanti (farmaci depressori del SNC, ipotermia) che possono interferire col quadro clinico**
- **Situazioni che non consentano l'esecuzione dei riflessi del tronco o EEG**
- **Situazioni che non consentano una diagnosi eziopato-genetica certa**
- **Bambini di età inferiore ad un anno sottoposti a manovre rianimatorie.**

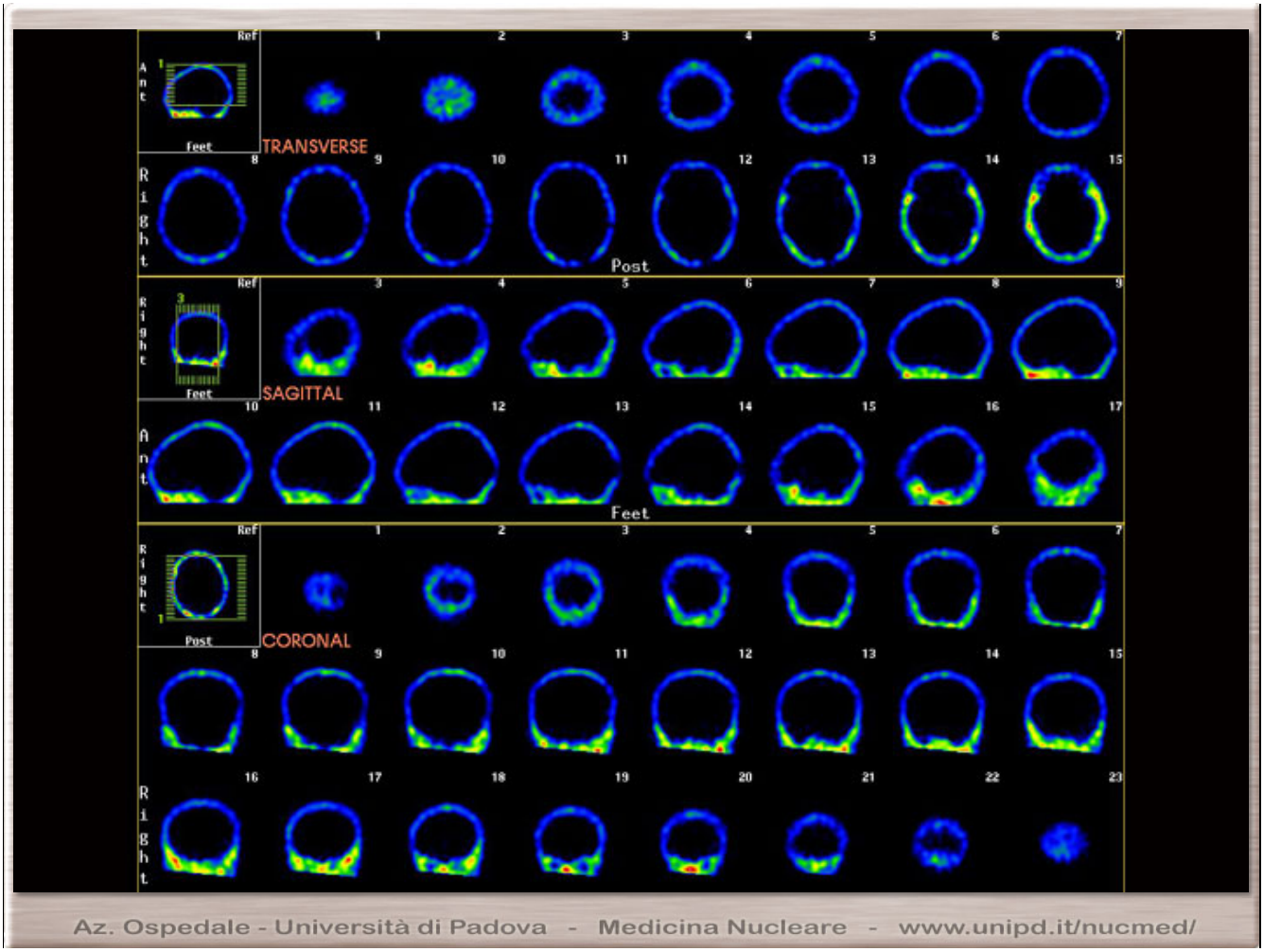
TRANSVERSE
SAGITTAL
CORONAL
Ant
Right
Feet
Post
Az. Ospedale - Università di Padova - Medicina Nucleare - www.unipd.it/nucmed/

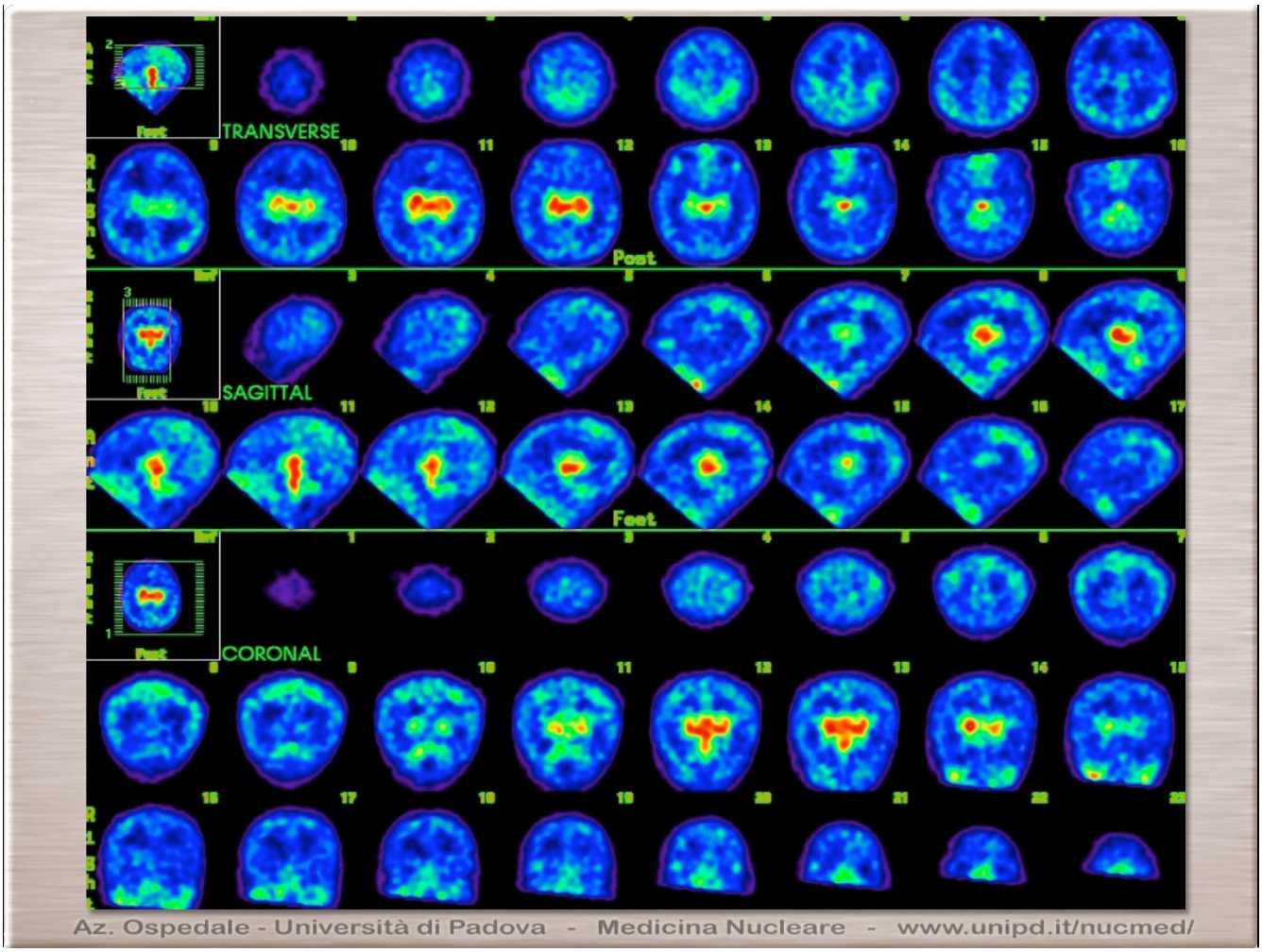
TRANSVERSE
SAGITTAL
CORONAL
Ant
Right
Feet
Post
Az. Ospedale - Università di Padova - Medicina Nucleare - www.unipd.it/nucmed/

SPET CEREBRALE PERFUSORIA

TRAUMI

SPET CEREBRALE PERFUSORIA - TRAUMA

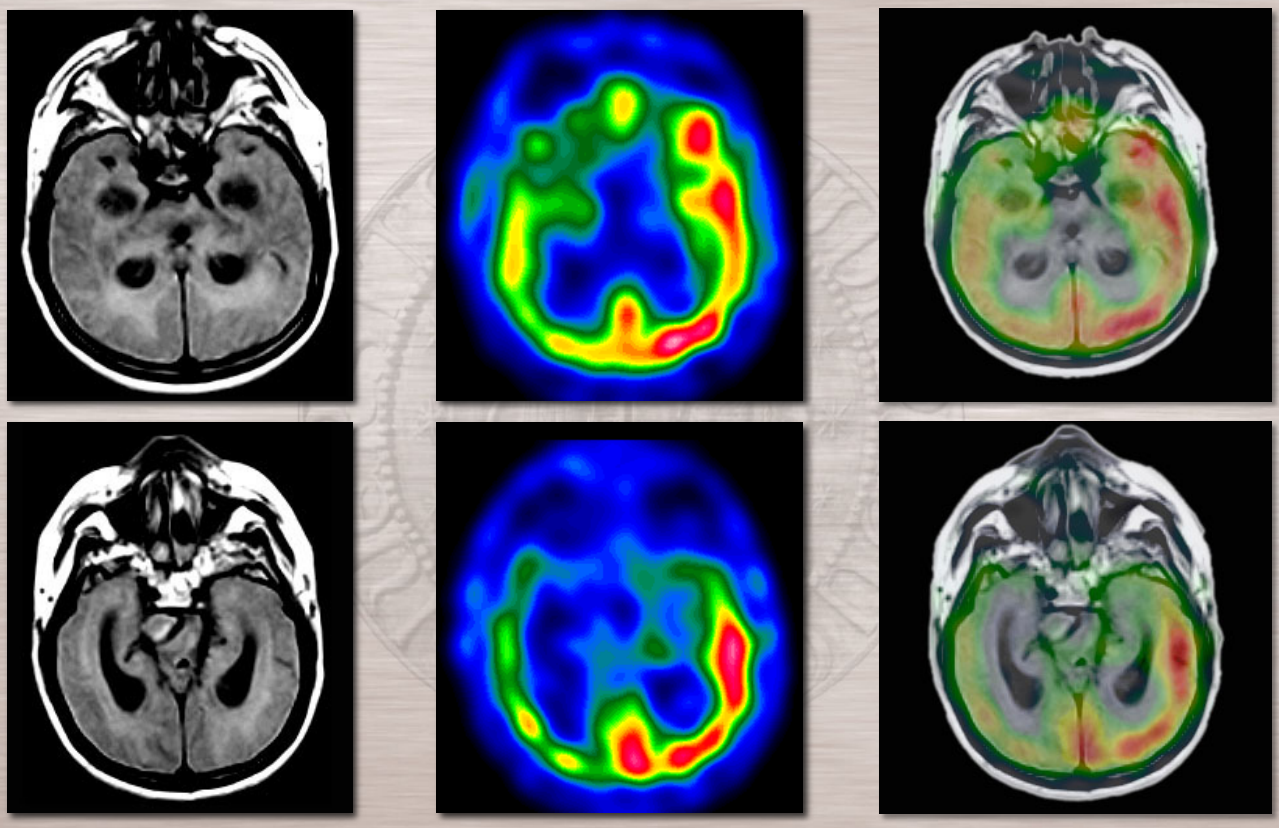

SPET CEREBRALE

RADIOFARMACI RECETTORIALI

Radiofarmaci recettoriali - DOPAMINA

DOPAMINA		
D1	**D2**	**DAT**
^{11}C-SCH 23390	^{11}C-Raclopride	^{11}C-PE21
^{11}C-NNC 112	^{11}C-FLB 457	^{11}C-BETA-CIT-FE
	^{11}C-NMSP	^{18}F-BETA-CFT
	^{18}F-Fallypride	^{18}F-BETA-CIT-FP
	^{18}F-Fluoretilspiperone	^{123}I-altropane
	^{123}I-IBZM	^{99m}Tc-Trodat-1
	^{123}I-epidepride	**^{123}I-DatScan**

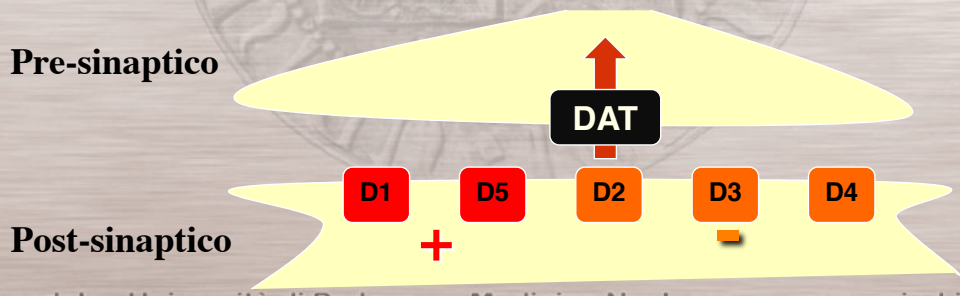

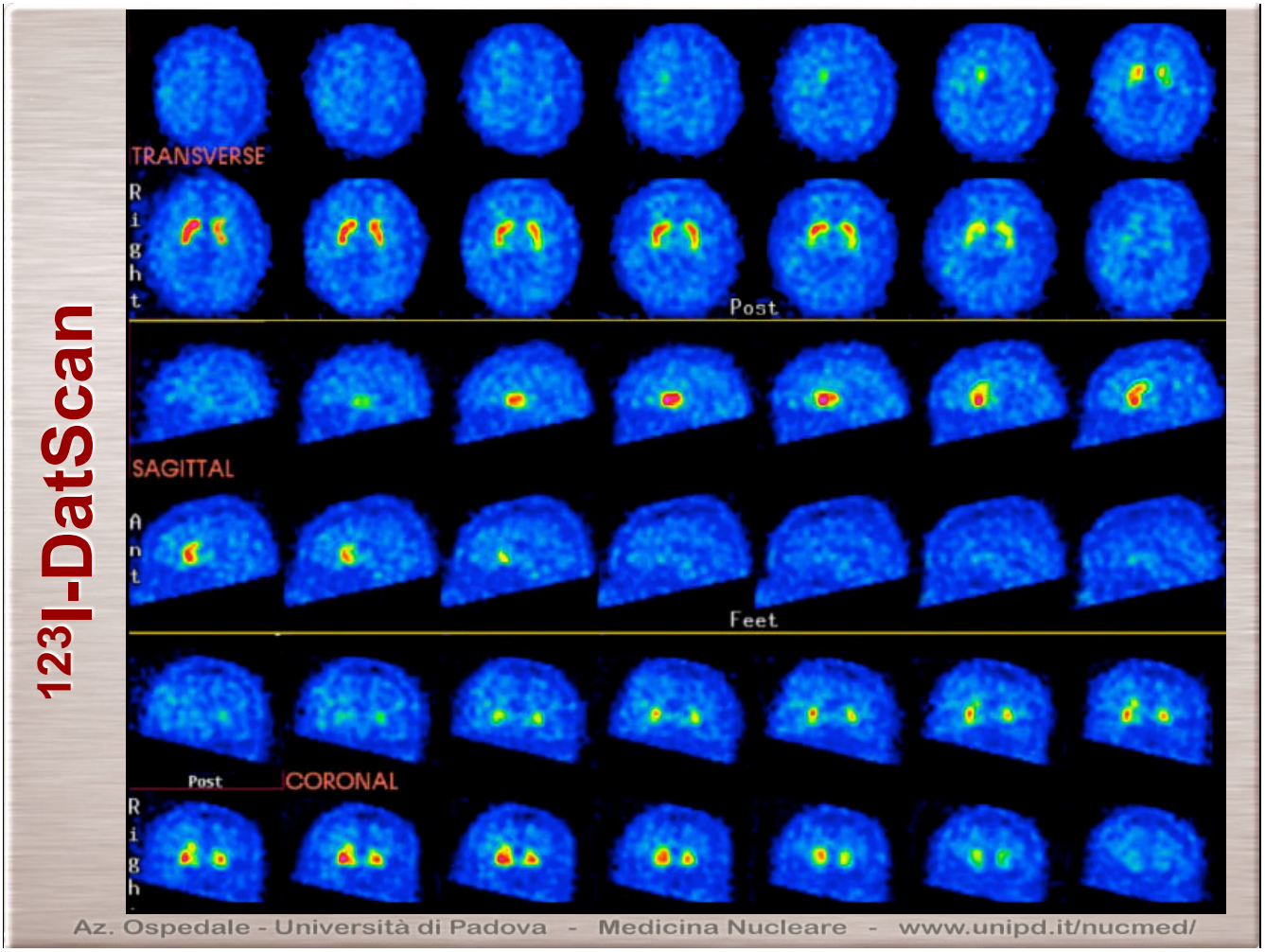

SPET CEREBRALE con ^{123}I-DatScan

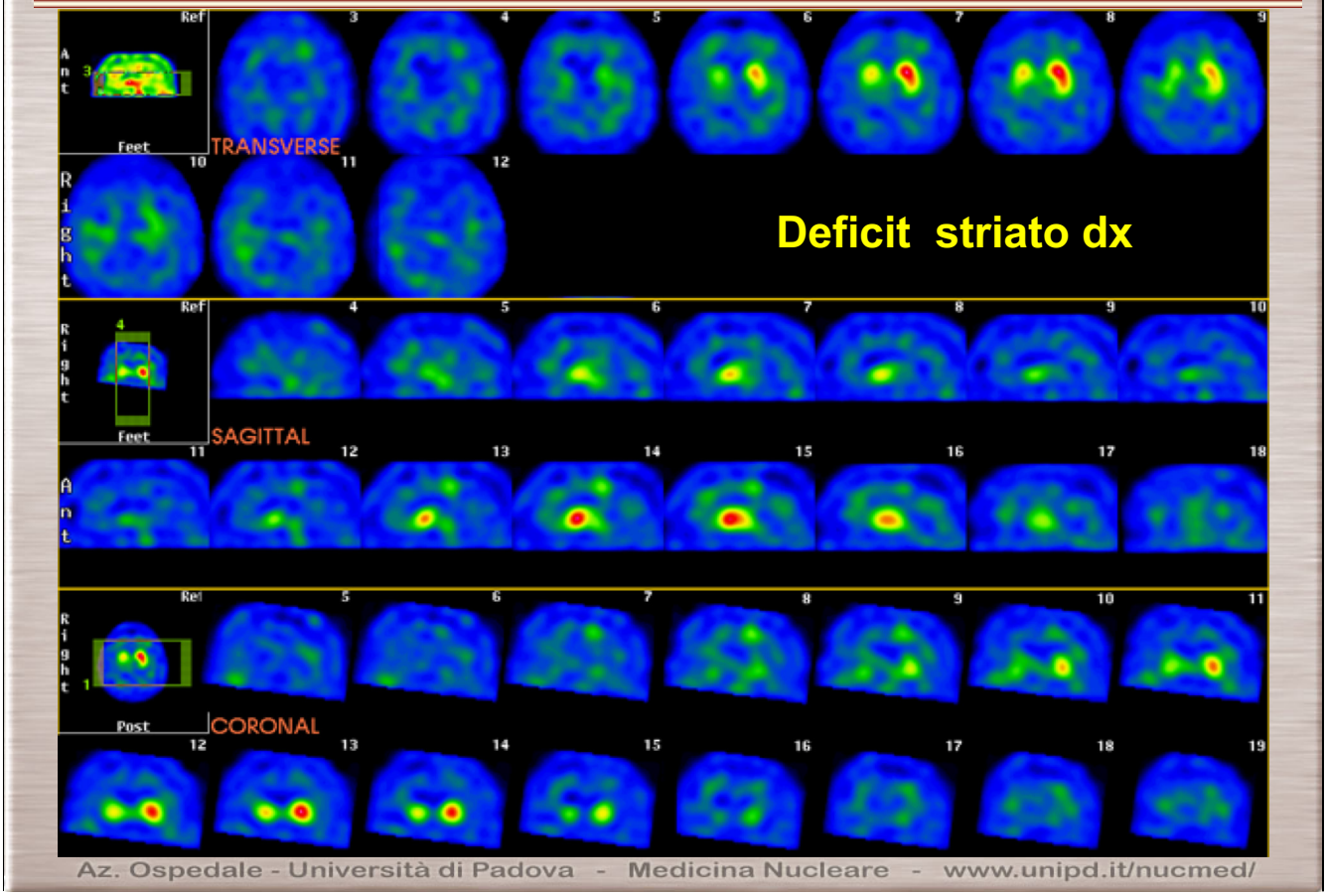

PET-CT CEREBRALE

- Stato dell'arte in MN
- Fusione "intrinseca" di immagini PET e CT
- Elevata informazione morfo-funzionale

RADIOFARMACI PET

GLUCIDI AMINOACIDI NUCLEOSIDI

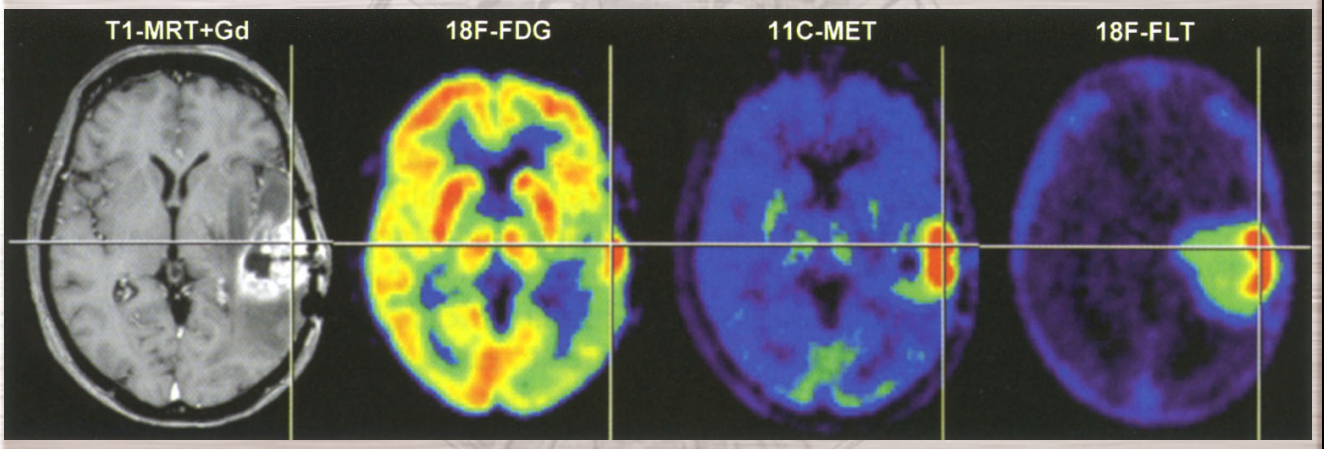

PET CEREBRALE

^{18}F-FDG PER LO STUDIO DEL METABOLISMO GLUCIDICO

PET CEREBRALE con ^{18}FDG - normale

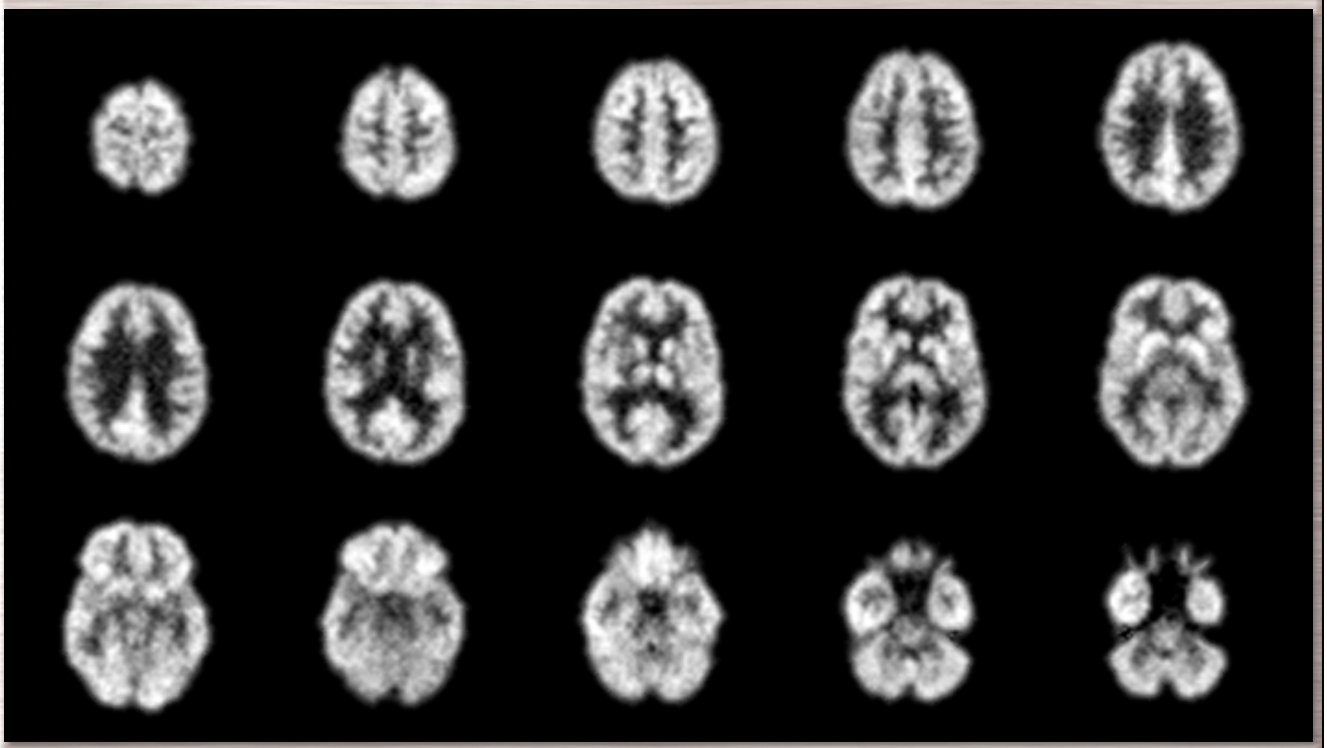

PET CEREBRALE con ^{18}FDG - normale

SVILUPPO METABOLICO DEL CERVELLO

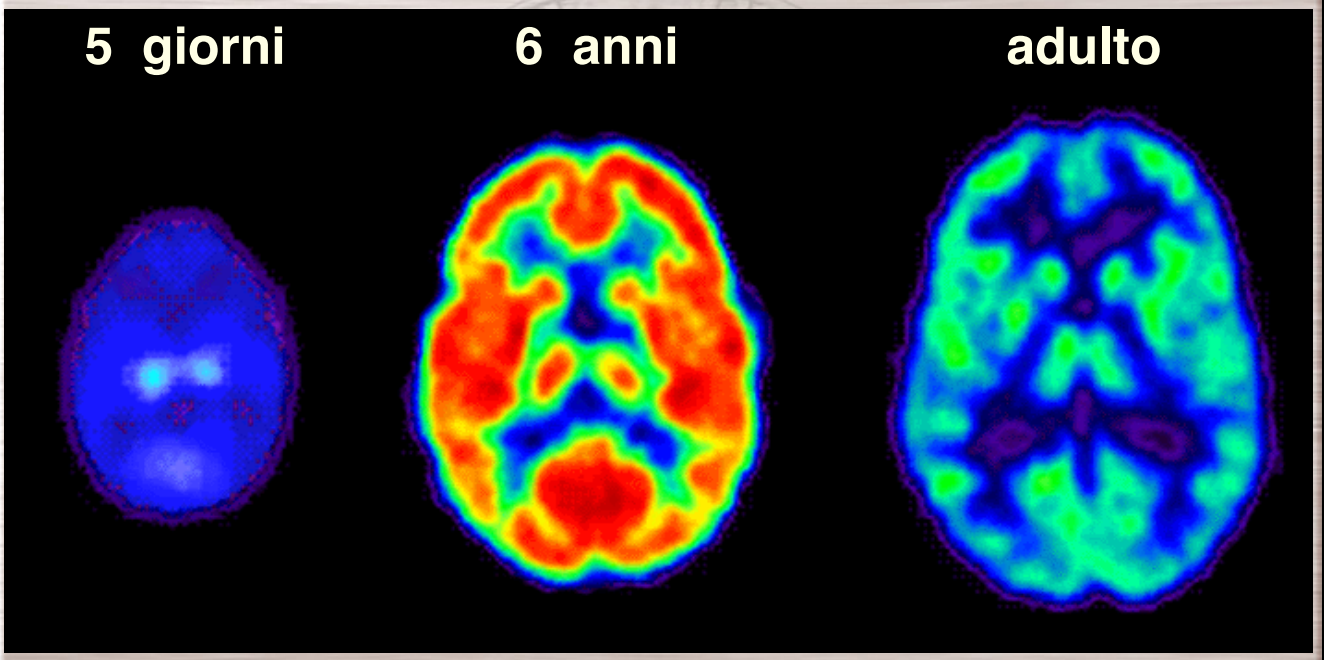

PET CEREBRALE con ^{18}FDG - Astrocitoma

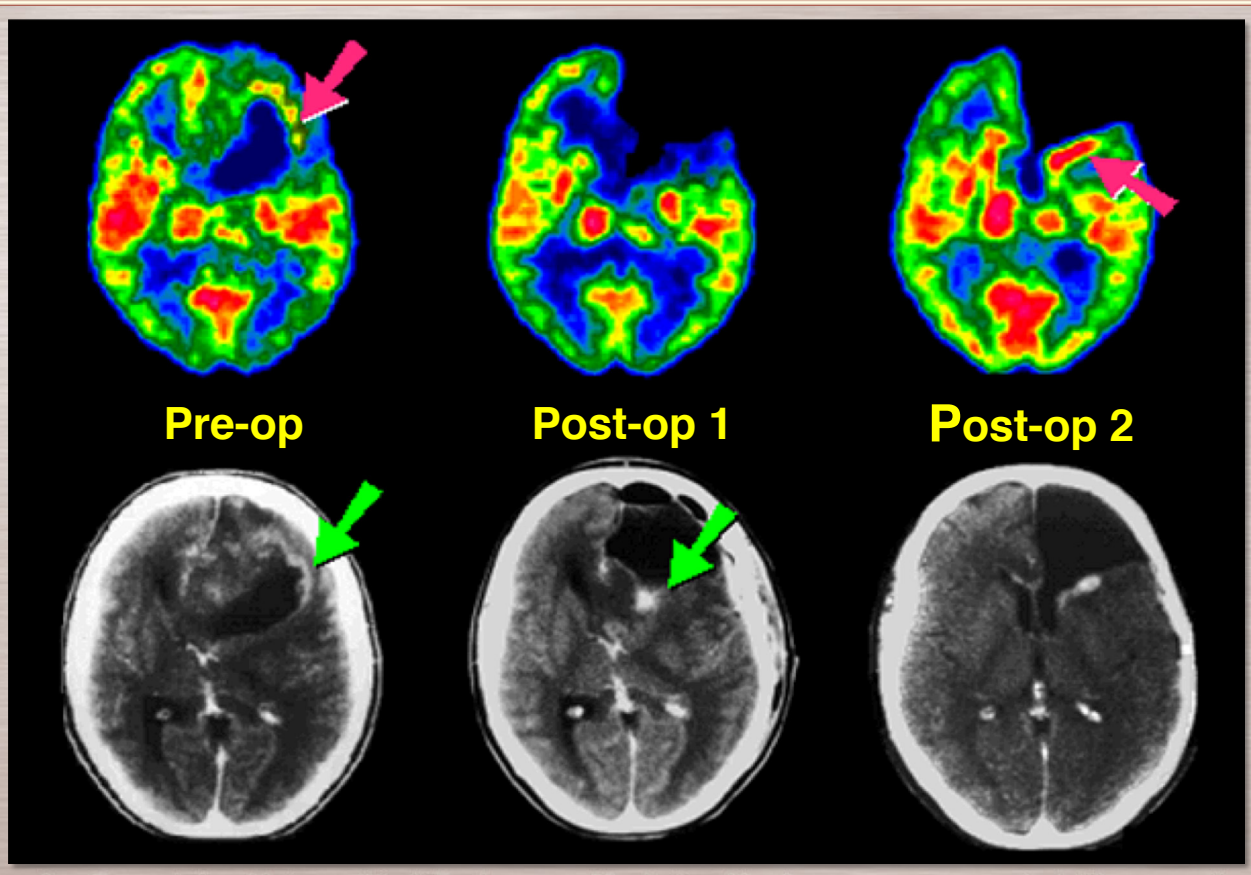

^{18}F-FDG PET - ALZHEIMER

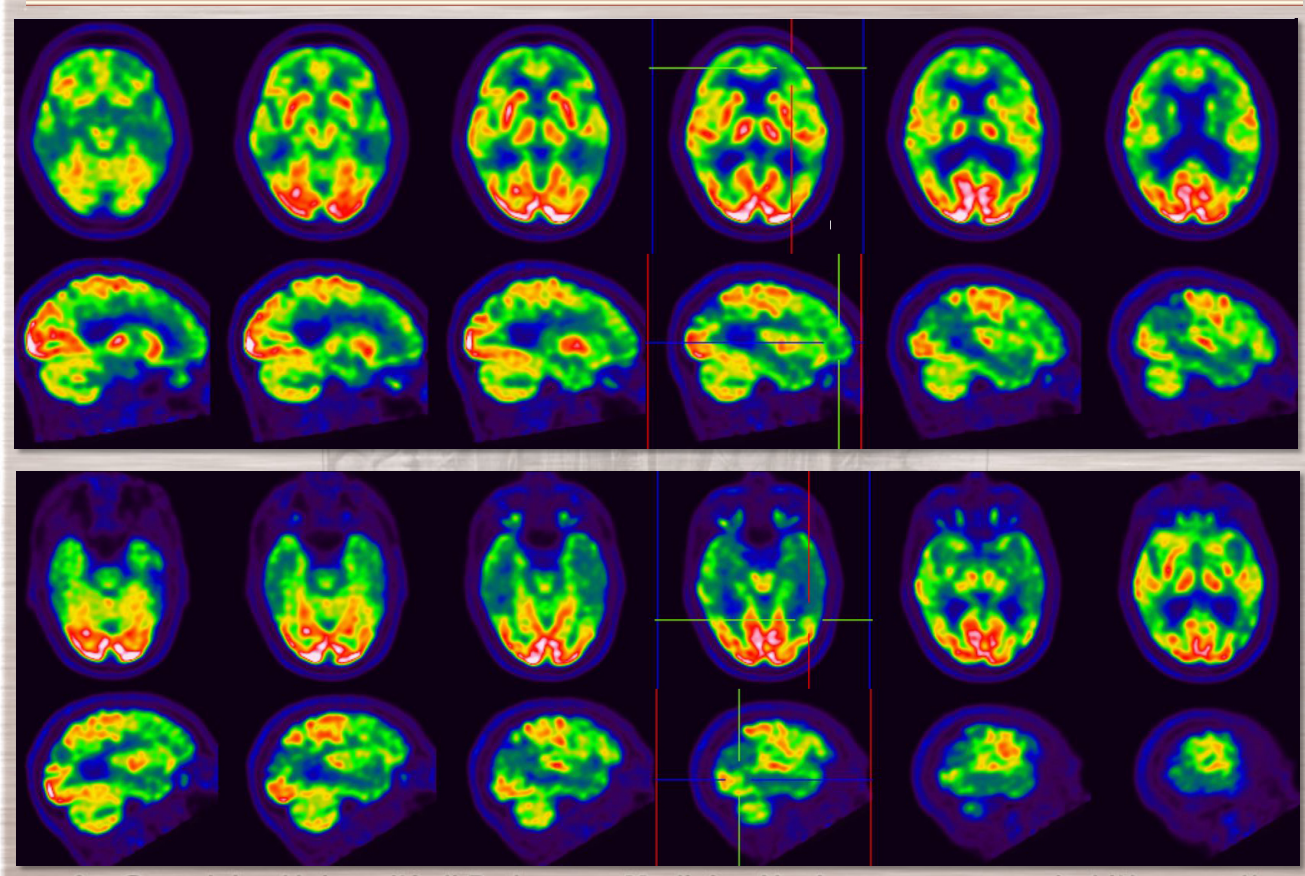

^{18}F-FDG PET - ALZHEIMER

Esordio

15 mesi

30 mesi
Demenza
conclamata

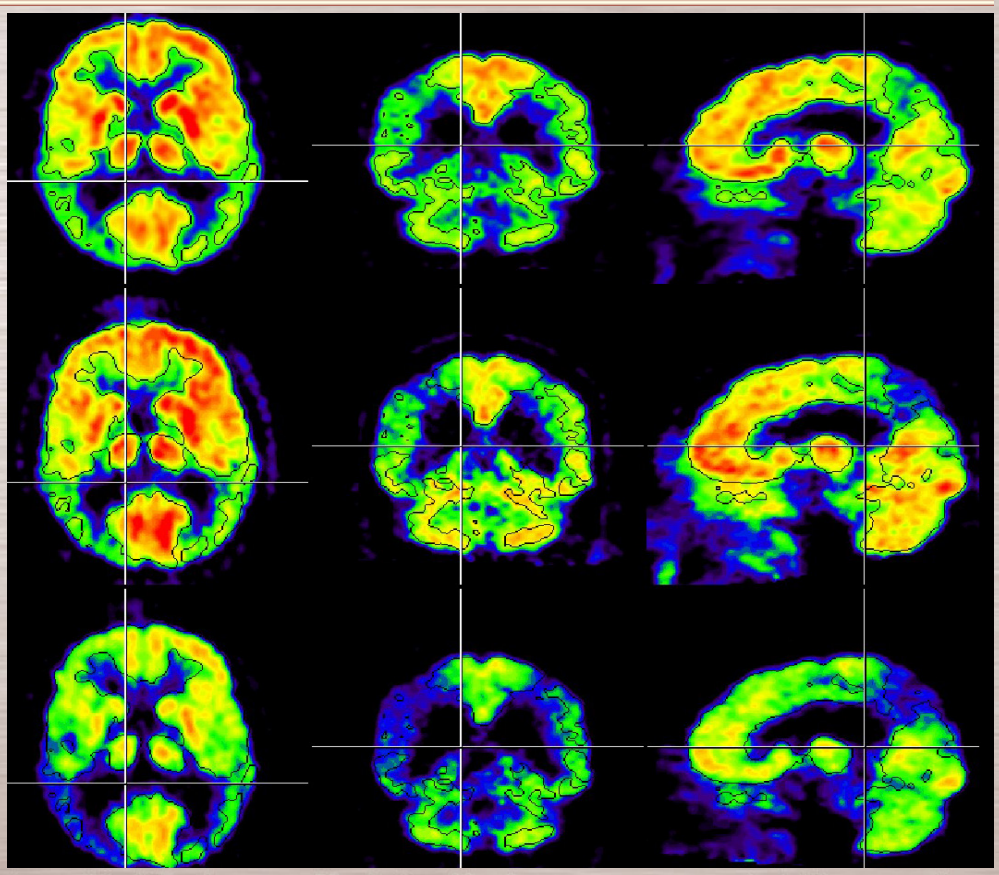

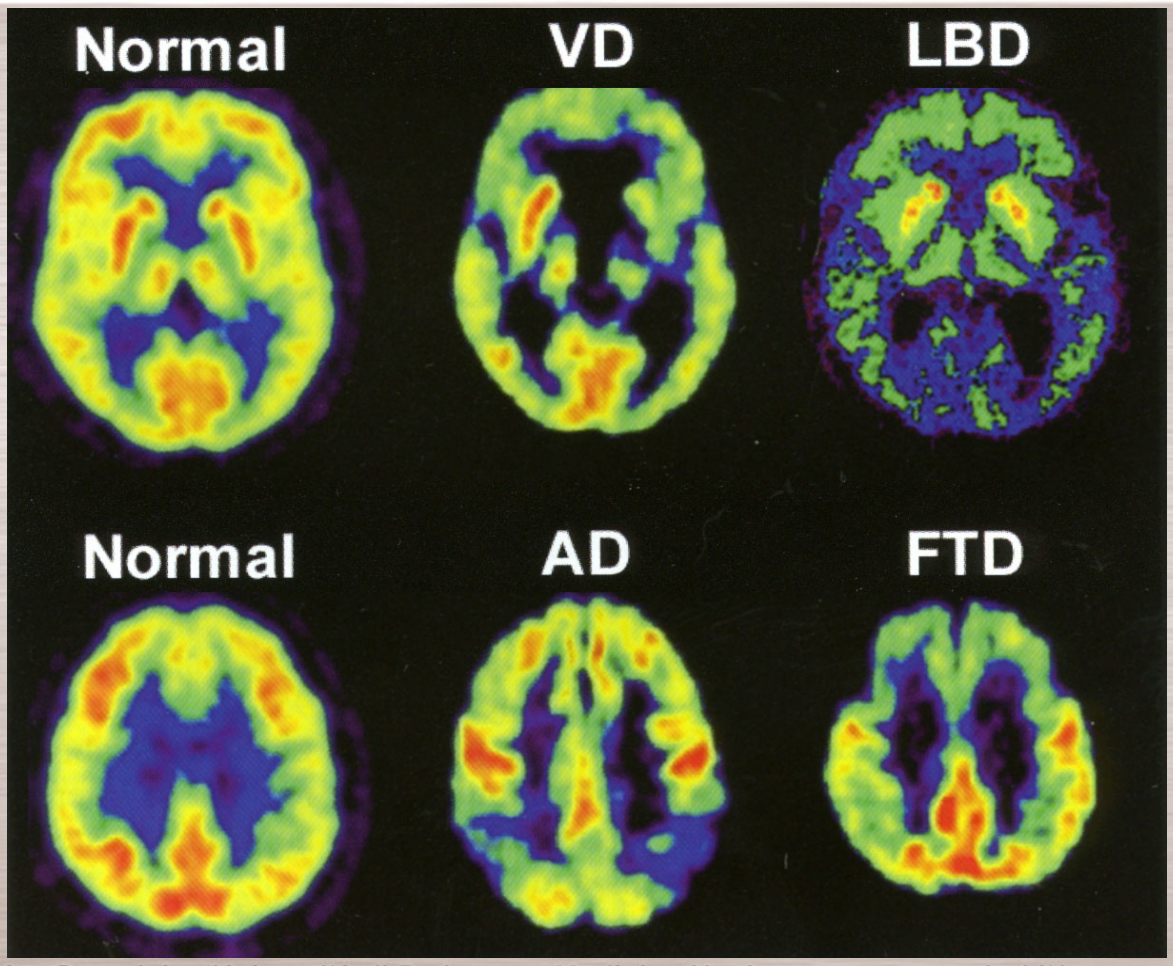

PET CEREBRALE

RADIOFARMACI RECETTORIALI

Az. Ospedale - Università di Padova - Medicina Nucleare - www.unipd.it/nucmed/

PET CEREBRALE - normale

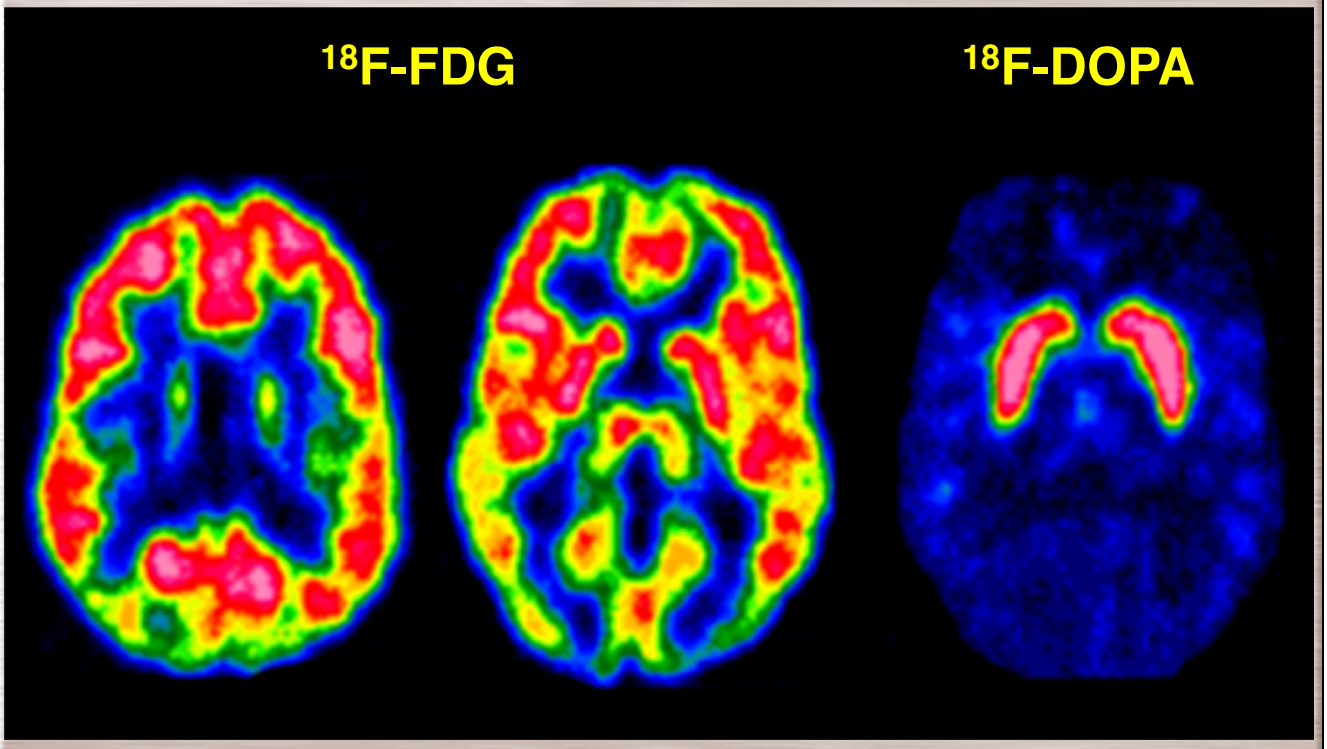

Az. Ospedale - Università di Padova - Medicina Nucleare - www.unipd.it/nucmed/

PET CEREBRALE - PARKINSON

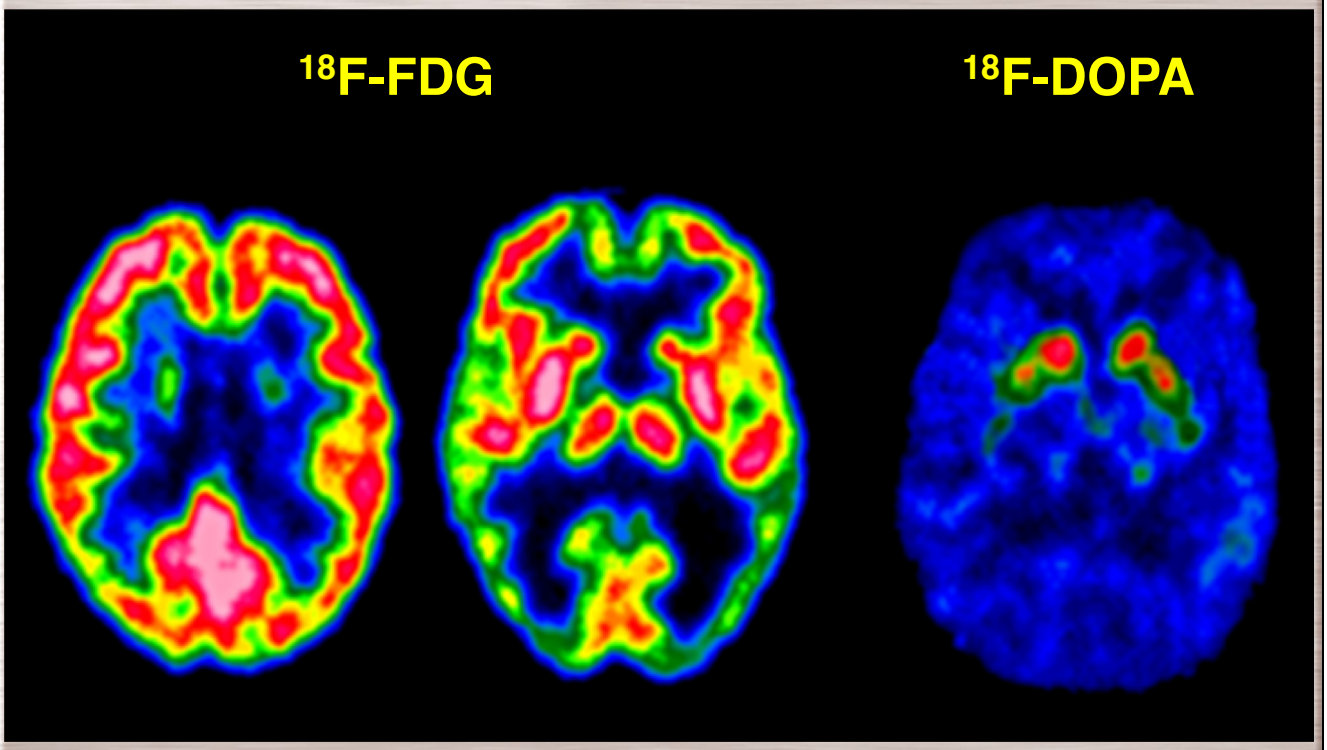

Az. Ospedale - Università di Padova - Medicina Nucleare - www.unipd.it/nucmed/

PET-MRI CEREBRALE

- Stato dell'arte per la ricerca in MN
- Fusione "intrinseca" immagini PET + MR
- Elevata informazione morfo-funzionale
- Particolarmente indicata in campo neurologico

PET/MRI

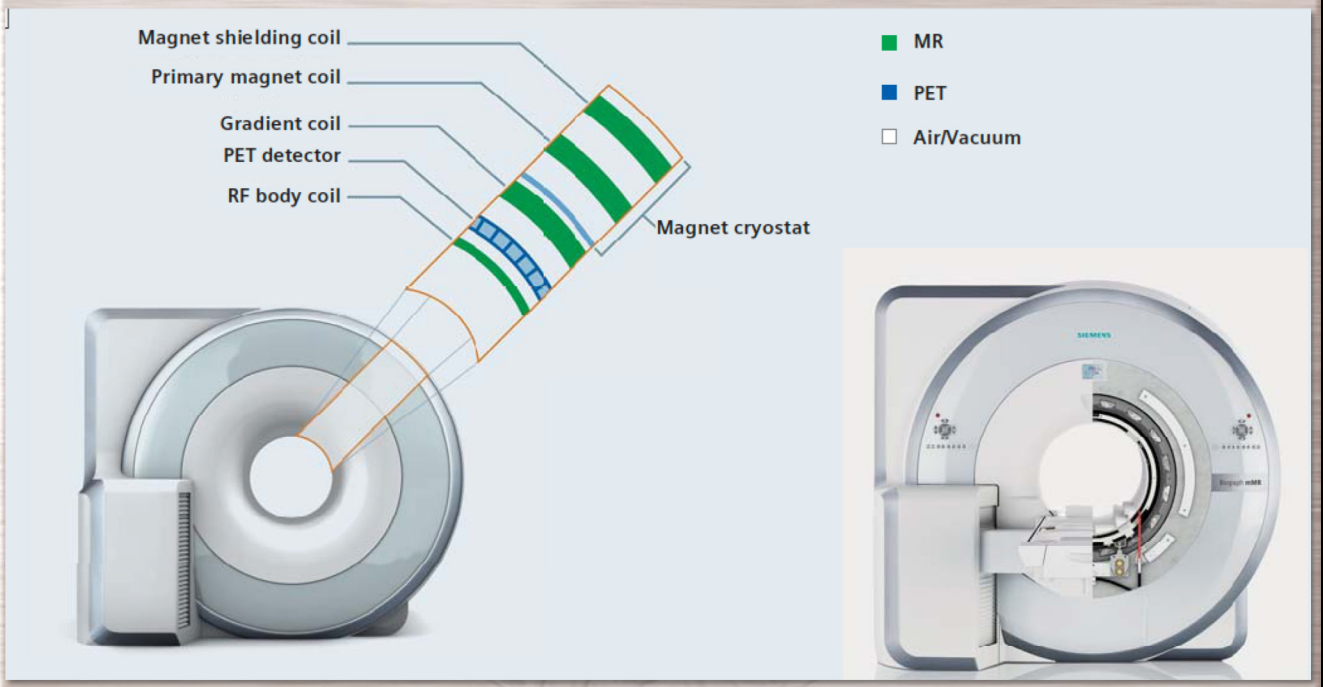

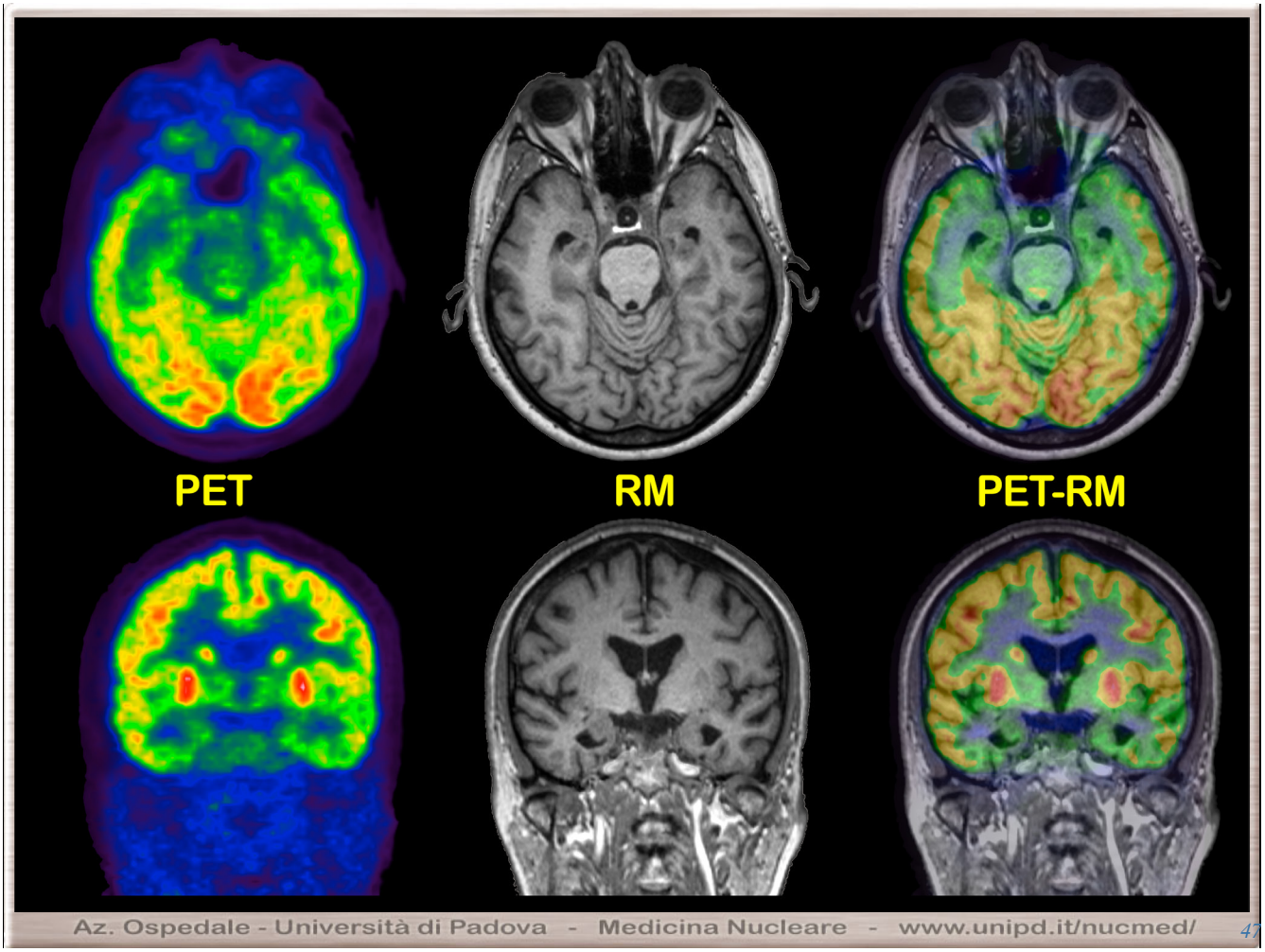
PET
RM
PET-RM
Az. Ospedale - Università di Padova - Medicina Nucleare - www.unipd.it/nucmed/

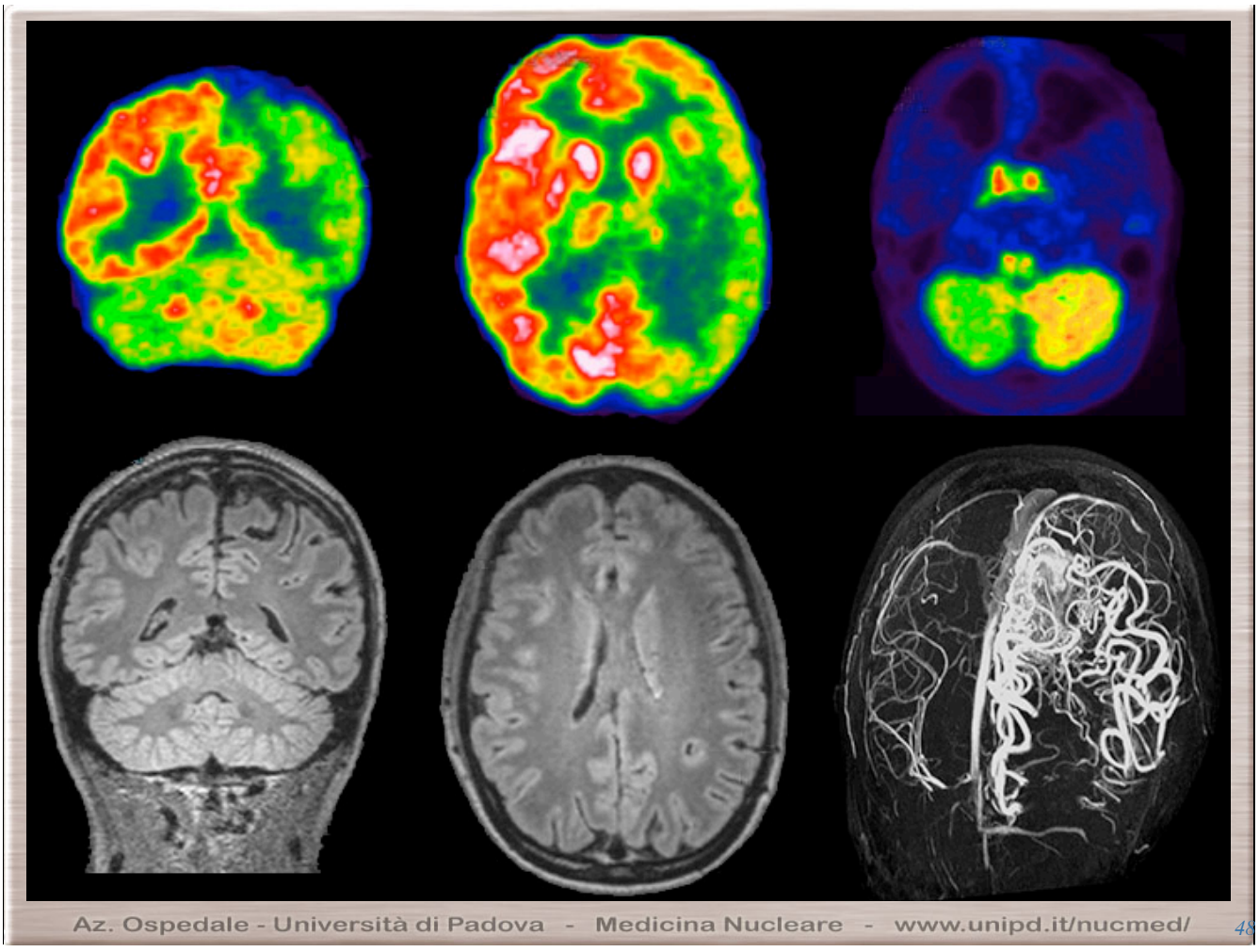
Az. Ospedale - Università di Padova - Medicina Nucleare - www.unipd.it/nucmed/

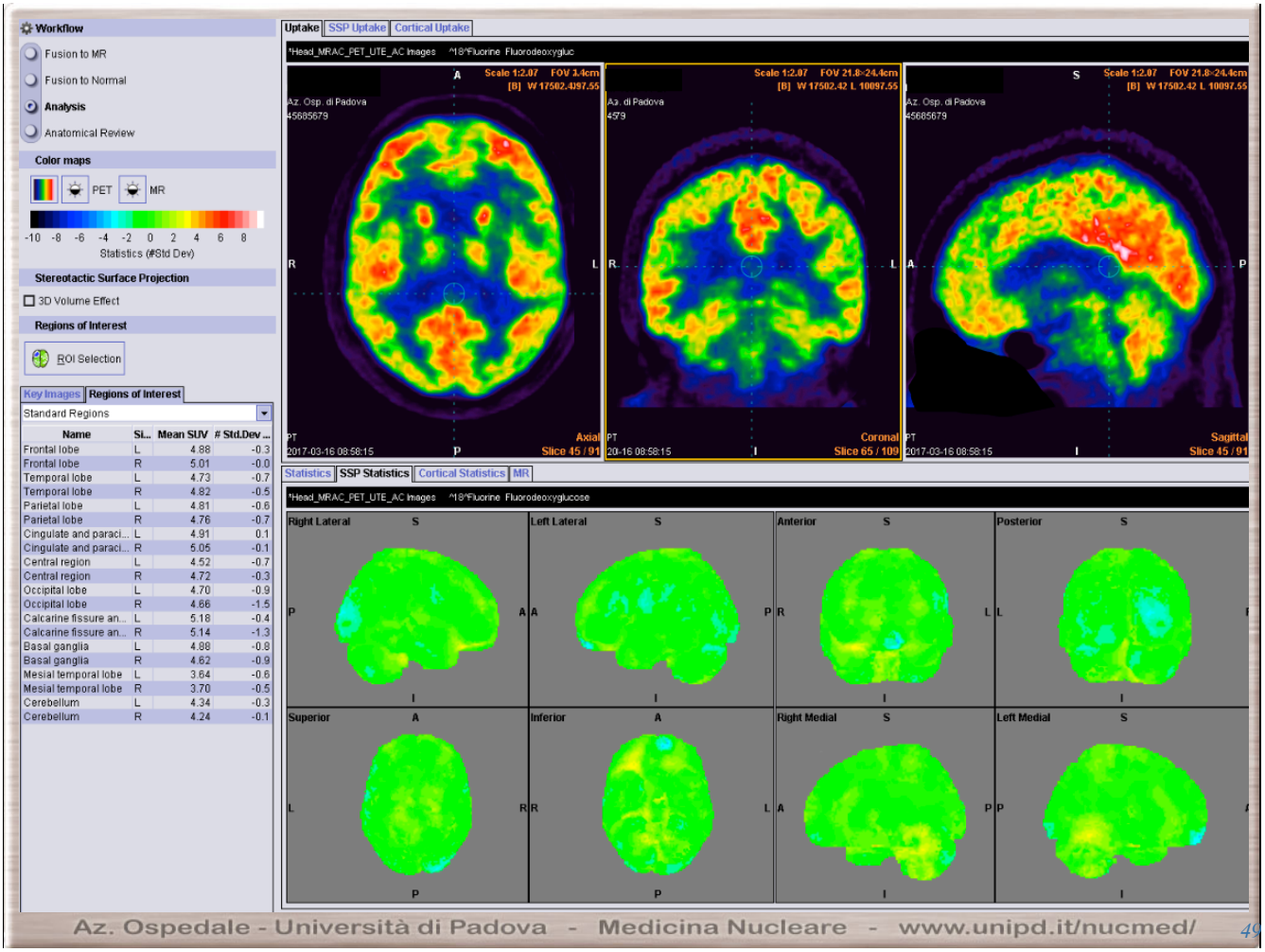
Workflow
Fusion to MR
Fusion to Normal
Analysis
Anatomical Review
Color maps
PET
MR
-10 -8 -6 -4 -2 0 2 4 6 8
Statistics (#Std Dev)
Stereotactic Surface Projection
3D Volume Effect
Regions of Interest
ROI Selection
Key Images
Regions of Interest
Standard Regions
Name
Sl...
Mean SUV
Std.Dev ...
Frontal lobe L 4.88 -0.3
Frontal lobe R 5.01 -0.0
Temporal lobe L 4.73 -0.7
Temporal lobe R 4.82 -0.5
Parietal lobe L 4.81 -0.6
Parietal lobe R 4.76 -0.7
Cingulate and paraci... L 4.91 0.1
Cingulate and paraci... R 5.05 -0.1
Central region L 4.52 -0.7
Central region R 4.72 -0.3
Occipital lobe L 4.70 -0.9
Occipital lobe R 4.66 -1.5
Calcarine fissure an... L 5.18 -0.4
Calcarine fissure an... R 5.14 -1.3
Basal ganglia L 4.88 -0.8
Basal ganglia R 4.62 -0.9
Mesial temporal lobe L 3.64 -0.6
Mesial temporal lobe R 3.70 -0.5
Cerebellum L 4.34 -0.3
Cerebellum R 4.24 -0.1
Uptake
SSP Uptake
Cortical Uptake
Axial
Coronal
Sagittal
Statistics
SSP Statistics
Cortical Statistics
MR
Right Lateral
Left Lateral
Anterior
Posterior
Superior
Inferior
Right Medial
Left Medial
Az. Ospedale - Università di Padova - Medicina Nucleare - www.unipd.it/nucmed/
49

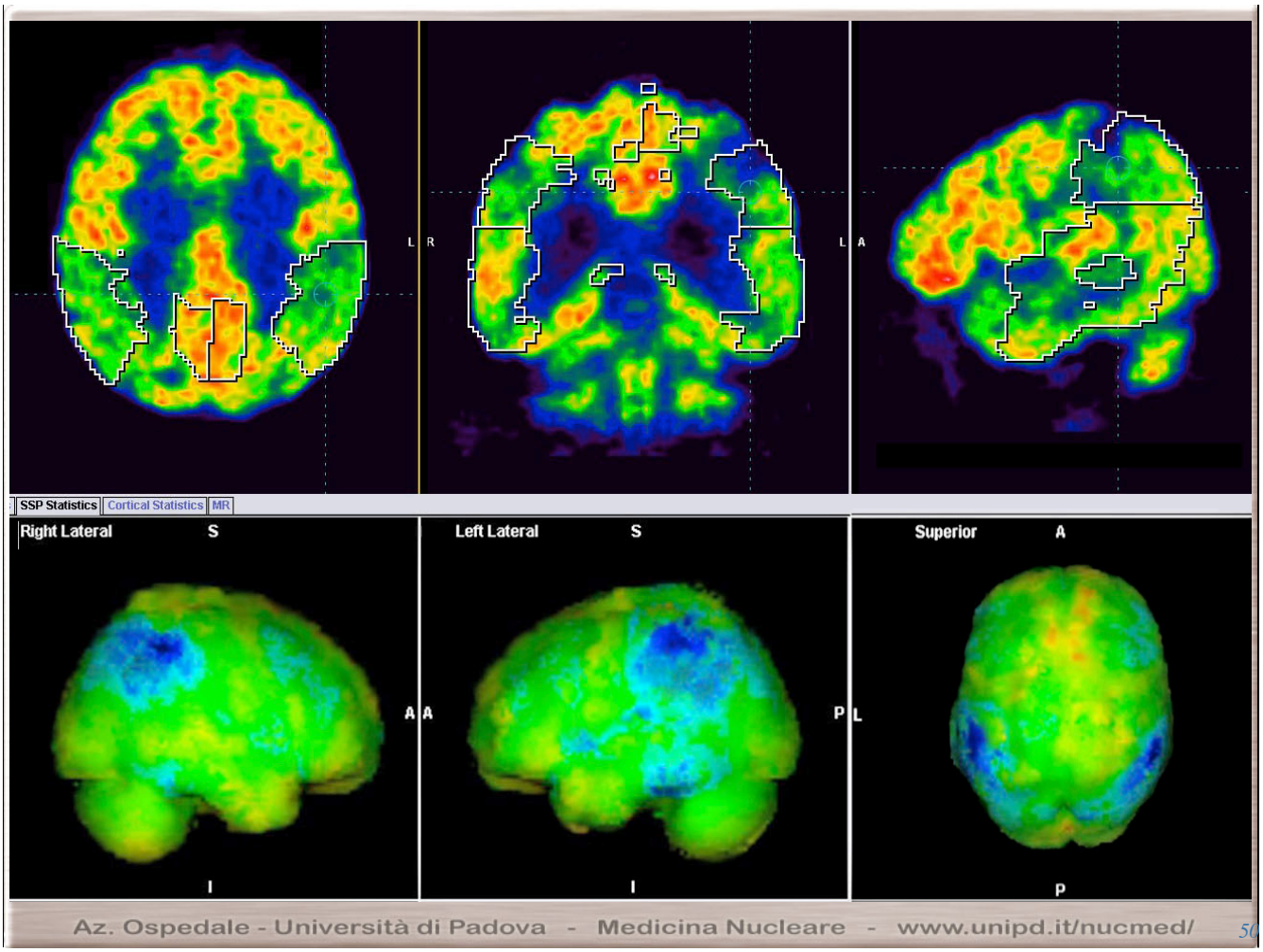
SSP Statistics
Cortical Statistics
MR
Right Lateral
Left Lateral
Superior
Az. Ospedale - Università di Padova - Medicina Nucleare - www.unipd.it/nucmed/
50

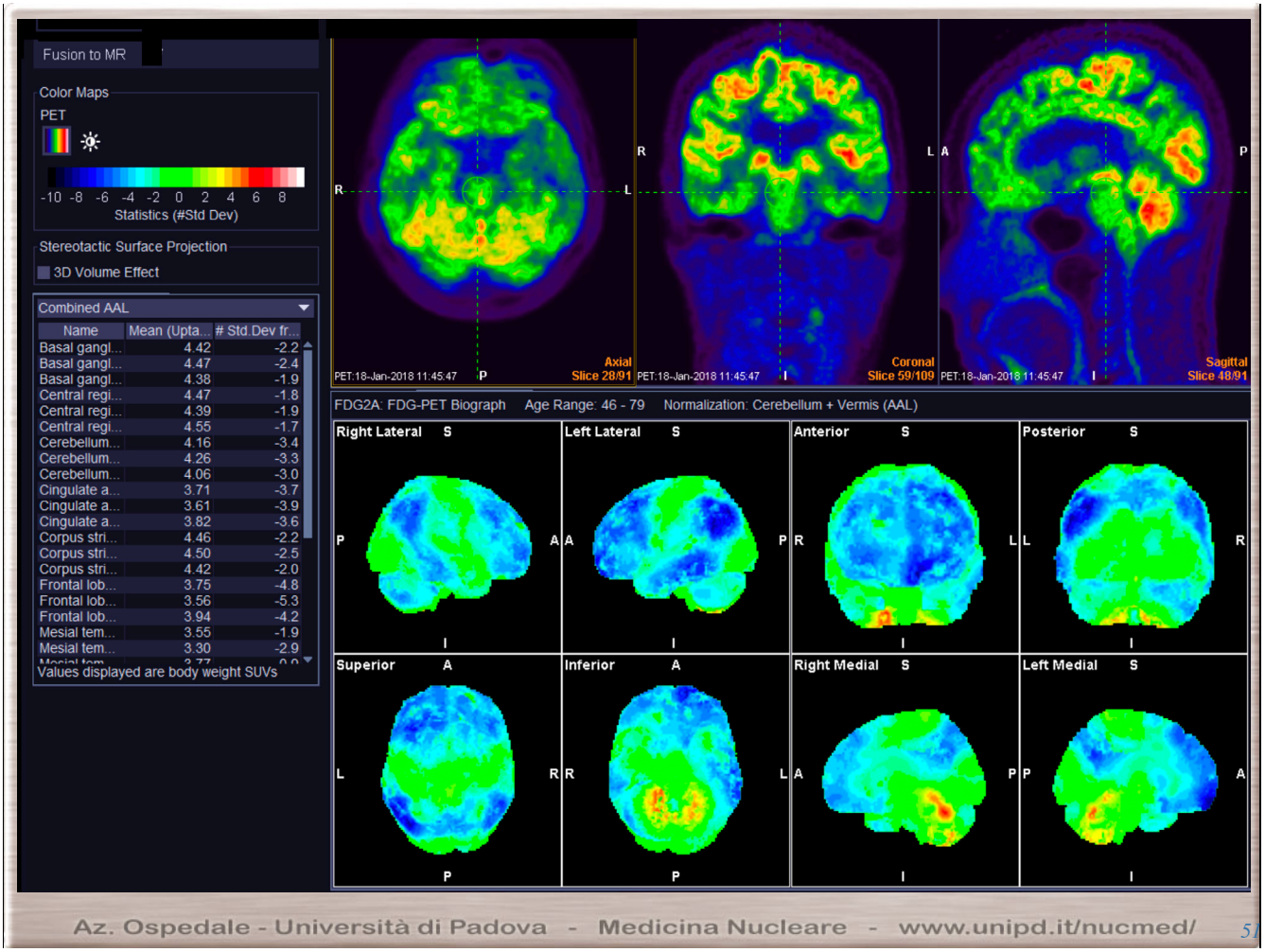
Fusion to MR
Color Maps
PET
-10 -8 -6 -4 -2 0 2 4 6 8
Statistics (#Std Dev)
Stereotactic Surface Projection
3D Volume Effect
Combined AAL
Name | Mean (Upta... | # Std.Dev fr...
Basal gangl... 4.42 -2.2
Basal gangl... 4.47 -2.4
Basal gangl... 4.38 -1.9
Central regi... 4.47 -1.8
Central regi... 4.39 -1.9
Central regi... 4.55 -1.7
Cerebellum... 4.16 -3.4
Cerebellum... 4.26 -3.3
Cerebellum... 4.06 -3.0
Cingulate a... 3.71 -3.7
Cingulate a... 3.61 -3.9
Cingulate a... 3.82 -3.6
Corpus stri... 4.46 -2.2
Corpus stri... 4.50 -2.5
Corpus stri... 4.42 -2.0
Frontal lob... 3.75 -4.8
Frontal lob... 3.56 -5.3
Frontal lob... 3.94 -4.2
Mesial tem... 3.55 -1.9
Mesial tem... 3.30 -2.9
Values displayed are body weight SUVs
PET:18-Jan-2018 11:45:47
Axial Slice 28/91
Coronal Slice 59/109
Sagittal Slice 48/91
FDG2A: FDG-PET Biograph
Age Range: 46 - 79
Normalization: Cerebellum + Vermis (AAL)
Right Lateral
Left Lateral
Anterior
Posterior
Superior
Inferior
Right Medial
Left Medial